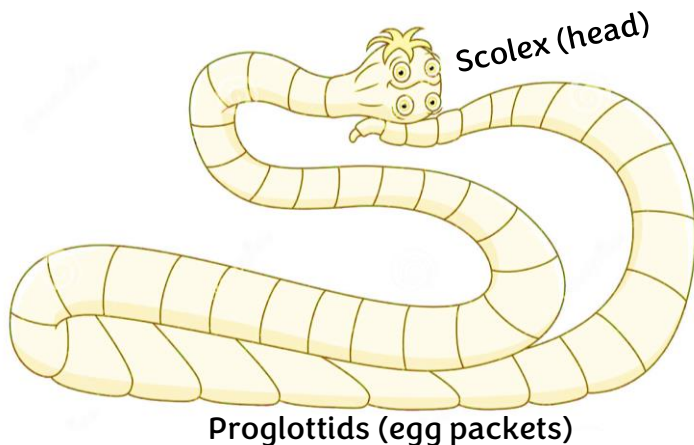


# TAPEWORMS

## Problem or not?

Tapeworms are big, flat, white, ribbon-like worms (cestodes) that live as adults in the small intestines of their host. The species of tapeworm that most commonly infects small ruminants is *Moniezia expansa*. It has an indirect life cycle, with pasture mites as the intermediate host. Tapeworms are the only worms that are visible in the feces. Their egg packets look like grains of rice.



### Not . . .

Tapeworm infections are generally considered harmless and asymptomatic, even when the worms are present in large numbers in young animals. Most research has shown no benefit to specifically treating for tapeworms.

### But . . .

A gut full of tapeworms may trigger colic or cause constipation in a lamb/kid. Though thought to be rare, heavy infections may result in intestinal blockage and death.

### And . . .

It has been hypothesized that heavy loads of tapeworms may alter intestinal function (gut motility) and predispose animals to other disease-causing organisms, including clostridium. Heavy tapeworm infections have been associated with outbreaks of enterotoxemia (overeating disease).

### Symptoms

Symptoms of tapeworm infection may include pot-belly, dullness, poor growth, weight loss, and diarrhea, not different from other parasites and diseases.



Oribatid mite

### Treatment

Most experts agree: it is not necessary to treat animals every time you see tapeworm segments in the manure. Of the three dewormer classes, the benzimidazole class (white dewormers) is the only one effective against tapeworms. Albendazole (Valbazen®) is labeled for tapeworm removal in sheep. The most effective drug for tapeworm removal is praziquantel. It is included in “first” drenches in many countries. Unfortunately, it is not labeled for any food animal in the US.

